

# Parkes Weber Syndrome Case Report

*by* Sariwana Sariwana

---

FILE	JURNAL_INTERNASIONAL_SCOPUS_DR._SARIWANA19.PDF (325.14K)	WORD COUNT	1587
TIME SUBMITTED	16-OCT-2020 03:15PM (UTC+0700)	CHARACTER COUNT	8577
SUBMISSION ID	1416947525		

## Parkes Weber syndrome. Case report.

Sariwana<sup>1</sup>, Tabri F.<sup>1</sup>, Widita W.<sup>1</sup>, Wahab S.<sup>1</sup>, Latief N.<sup>2</sup>, Budhiani S.<sup>1</sup>  
<sup>1</sup>Department of Dermatology and Venereology, <sup>2</sup>Department of Radiology  
Faculty of Medicine, Hasanuddin University, Makassar, Indonesia

### Summary

<sup>2</sup> Parkes Weber syndrome is a rare vascular malformation characterized by arteriovenous malformations, varicose veins and soft tissue hypertrophy of a limb. The diagnosis is confirmed by color doppler ultrasound that highlights vascular malformations, standard X-ray showing the limb volume variation and possible osteolytic lesions, and angiography or magnetic resonance imaging that make evident the damage of the blood vessels and the hypertrophy of the soft tissue. A case characterized by painful vascular malformations and hypertrophy of the left lower limb was here described for its rarity and to underline the need for appropriate investigations aimed at avoiding diagnostic errors and preventing further aggravation of symptoms.

### Keywords

Arteriovenous malformation, Parkes Weber syndrome, vascular malformation.

Vascular malformations (VM) are related to an error in the development of vessels that occurs between the fourth and tenth week of intrauterine life.

In most cases, these are sporadic events affecting 0.3% of the population (3) and can affect every type of vessel, arterial, venous, capillary and lymphatic (1).

The arterio-venous fistula (AVF) is an abnormal connection between the artery and the vein without the interposition of capillaries.

AVF can be acquired or congenital; even in the second case, it may become visible later in life due to trauma. AVF can affect any site, limbs, genitals, abdomen, thorax and also the central nervous system.

The prevalence of arteriovenous malformations (AVM) is not known. However, according to a study it is 1.1 / 100.000 (10).

Parkes Weber syndrome (PWS) was first described in 1907 (8) but due to its rarity the incidence is unknown. The initial clinical findings, which usually occur at birth (5), are various.

The pathogenesis of PWS is not yet fully understood but according to some Authors (8) genetic factors, in particular mutations of the RASA1 gene, play a significant role in many cases of PWS: the RASA1 gene that encodes the RAS GTPase p120 protein would be implicated in the development and organization of blood vessels.

A recent report (6) showed that a dysregulation of the EPHB4 / RASA1 / mTORC1 signals in endothelial cells caused by insufficient inactivation of RAS can interfere with the arterio-venous differentiation process and give rise to capillary, arterial and venous malformations.

Arterio-venous fistulas can be responsible for ischemic phenomena and heart failure (8).

**Case report**

A 7-year-old boy weighing 19 kg was first observed due to the presence of painful reddish lesions of the left lower limb present since birth.

The lesions bled following minimal trauma and the child could not fully extend the limb with consequent difficult walking. The family history was negative for similar lesions. There were no traumas in the personal history.

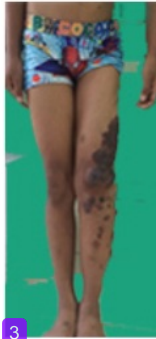

Fig. 1

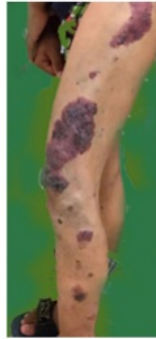

Fig. 2

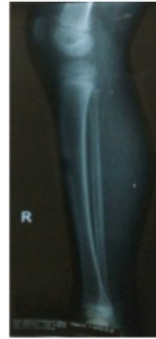

Fig. 3

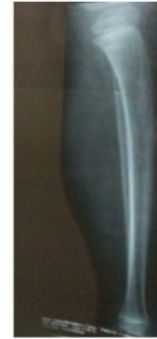

Fig. 4

Fig. 1, 2, 3, 4: Parkes-Weber syndrome with limb hypertrophy even visible on X-ray

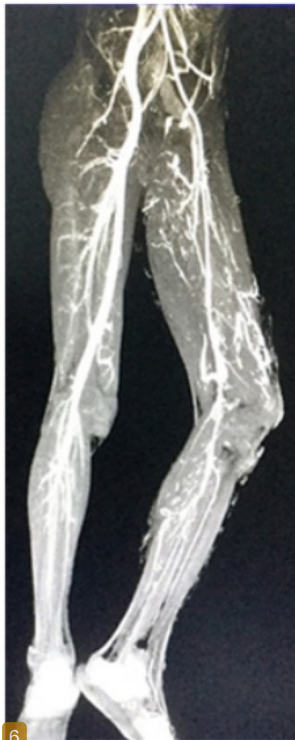


Fig. 5

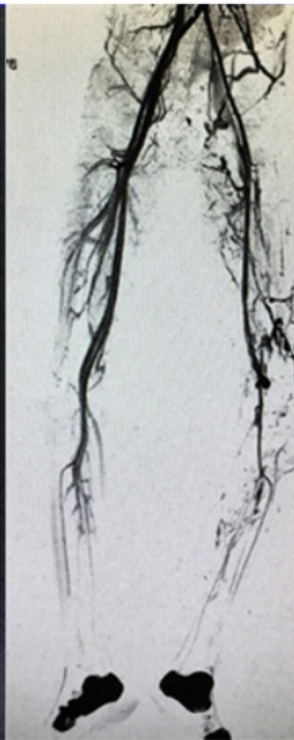

Fig. 6

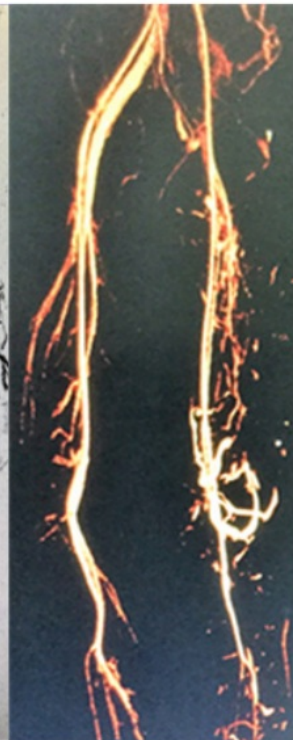

Fig. 7

Fig. 5, 6, 7: Superficial venous dilatation of the left large and small saphena.

Dermatological examination showed hyperpigmented warty plaques overlying pulsatile, warmer at palpation cutaneous tumefactions with evident and tortuous blood vessels. With respect to the contralateral limb the left lower limb was 3 cm longer with a circumference of 7 cm wider (Fig. 1, 2).

The laboratory examinations were within the normal limits; X-ray of the thorax, ECG and cardiac ultrasound did not show significant alterations. Radiography of the left lower limb (Fig. 3, 4) showed soft tissue hypertrophy in the absence of bone lesions. Color doppler showed intralesional flow that became more evident with the Valsalva maneuver, a large anechoic tubular structure that collapsed as a result of compression and venous monophasic waves. Color doppler therefore suggested the presence of arteriovenous fistulas or shunts. Angiography with multi-layer computed tomography showed superficial venous dilatation of the left large and small saphena (Fig. 5, 6, 7).

Clinical data and radiological investigations led to the diagnosis of Parkes Weber syndrome characterized in this case by varicose veins, arterio-venous shunts as evidenced by the early filling of dilated and tortuous veins and soft tissue hypertrophy. The patient was sent to vascular surgical consultation.

## Discussion

Vascular malformations affect the limbs, especially the lower limbs, rarely the trunk (2). PWS shows lesions of the limbs that worsen rapidly, varicose veins with signs of high-flow arteriovenous shunt such as edema, increased temperature, varicose veins and vibrations (1). Varicose veins are related to arteriovenous shunts, venous hypertension and failure of the deep venous system (13). Limb hypertrophy is due not only to venous and lymphatic stasis (2) but also to excessive soft tissue growth, varicose veins and bone lengthening (2).

PWS must be differentiated from Klippel Trenaunay syndrome (KTS), which also presents

hypertrophy of a limb associated with vascular malformations (4, 6).

While in PWS you can find varicose veins, hypertrophy of a limb and arteriovenous malformations, in Klippel-Trénaunay syndrome (KTS) varicose veins and hypertrophy of a limb are associated with port-wine stain, ie capillary malformations. In PWS there are mutations of RASA1 with involvement of both the mesoderm and the ectoderm, while in KTS there are no mutations of RASA1 and only the mesoderm is affected. From a prognostic point of view PWS can be fatal, while KTS has a good prognosis (7).

Vascular malformations of PWS usually worsen over time and may be complicated by recurrent skin infections due to lymphedema, by limb pain, ulceration (11), ischemia (12), bleeding after minimal trauma, heart failure due to high output, pelvis tilting and scoliosis (5). Cardiac anomalies can be caused by circulatory failure due to arterio-venous changes (2). Ulceration and ischemia are linked to the increase of flow in the venous vascular system with secondary hypertension and chronic venous failure. This results in the failure of the microcirculation with hypoxia (9).

In our patient, however, we did not find ulcerations or cardiac abnormalities.

Treatment of PWS is symptomatic. Compression therapy is useful for reducing the symptoms of chronic venous failure and lymphatic edema. In some cases it is possible to resort to surgical treatment. The latter is difficult and may require several intravascular procedures such as embolization, sclerotherapy, open surgery with arteriovenous fistula ligation. In the case of severe limb ischemia, limb amputation may be essential (13). These patients should be monitored periodically with radiological examinations. A multidisciplinary approach involving the pediatrician, radiologist and vascular surgeon is essential (8).

In conclusion, Parkes Weber syndrome is a rare vascular malformation characterized by arterio-venous fistulas. Differential diagnosis from Klippel Trenaunay syndrome can be made with color doppler, MRI and angioRM. Early diagnosis and appropriate treatments are necessary to limit the complications.

Address to <sup>9</sup>  
 Sariwana, M.D.  
 Department of Dermatology and Venereology  
 Faculty of Medicine, Hasanuddin University  
 Address; Jl. Perintis Kemerdekaan KM.  
 11 Tamalanrea, Makassar  
 South Sulawesi, Indonesia  
 Phone: +6281284700299, Fax: +62411582353  
 e-mail: drsariwana.hs@gmail.com

#### References

- 1) Banžic I., Branković M., Maksimović Ž. et Al. 2017. Diagnostic and management paradigms: A systematic review. *Phlebology* 32 (6): 371-83.
- 2) Bojakowski K., Janusz G., Grabowska I. et Al. 2015. Rat model of Parkes Weber syndrome. *PLoS One* 10 (7): e0133752.
- 3) Boon L.M., Enjolras O., Mulliken J.B., Vikkula M. 2011. Vascular malformations. In: Irvine A., Hoeger P., Yan A. (eds.), *Harper's Textbook of Pediatric Dermatology*, Wiley-Blackwell, Oxford (UK) 2011, vol. 1, pp. 112.1-112.24.
- 4) Chagas C.A.A., Pires L.A.S., Babinski M.A., Leite T.F.dO. 2017. Klippel-Trenaunay and Parkes-Weber syndromes: two case reports. *Jornal Vascular Brasileiro* 16 (4): 320-4.
- 5) Ferreira M.S., Francisco T., Tavares D. 2013. Challenges in orthopaedic management of Parkes-Weber syndrome. *BMJ Case Rep.* 2013: bcr2013008800.
- 6) Forbes N., Walwyn M., Rao G. et Al. 2013. Klippel-Trenaunay syndrome. *West Indian Med. J.* 62 (3): 254-6.
- 7) Ghia D.H., Nayak C.S., Madke B.S., Gadkari R.P. 2014. Stewart-Bluefarb acroangiokeratosis in a case of Parkes-Weber syndrome. *Indian J. Dermatol.* 59 (4): 406-8.
- 8) Goldsmith P. 2016. Parkes-Weber syndrome. In: Griffiths C.E.M., Barker J., Bleiker T., Calmers R., Creamer D. (eds.), *Rook's Textbook of Dermatology*. Wiley-Blackwell, Oxford (UK), 2016. pp. 103.25-103.27.
- 9) Hoffmann F., Sondermann W., Alkhater M. et Al. 2016. Chronic foot ulcer caused by Parkes Weber syndrome. *Int. Wound J.* 13 (5):1092-4.
- 10) Jessurun G.A., Kamphuis D.J., Van der Zande F.H., Nossent J.C. 1993. Cerebral arteriovenous malformations in the Netherlands Antilles: high prevalence of hereditary hemorrhagic telangiectasia-related single and multiple cerebral arteriovenous malformations. *Clin. Neurol. Neurosurg.* 95 (3): 193-8.
- 11) Kondapavuluri B.K., Bharadwaj R.N., Shaikh S. et Al. 2015. Parkes Weber syndrome involving right lower limb: a case report. *Indian J. Surg.* 77 (Suppl. 1):130-4.
- 12) Yahata T., Takeuchi A., Yoshida S., Tsuchiya H. 2014. Distinctive features of stump volume change in a fresh lower limb amputee with Parkes-Weber syndrome. *BMJ Case Rep.* 2014: bcr2014206315.
- 13) Zegrocka-Stendel O., Bojakowski K., Dutkiewicz M. et Al. 2015. New protoescigenin derivative for the treatment of Parkes Weber syndrome. *PeerJ PrePrints* 3: e1598v1.

# Parkes Weber Syndrome Case Report

---

## ORIGINALITY REPORT

---

% **11**

SIMILARITY INDEX

% **8**

INTERNET SOURCES

% **9**

PUBLICATIONS

% **0**

STUDENT PAPERS

---

## PRIMARY SOURCES

---

**1** Krzysztof Bojakowski, Gabriela Janusz, Iwona Grabowska, Oliwia Zegrocka-Stendel et al. "Rat Model of Parkes Weber Syndrome", PLOS ONE, 2015 **%3**  
Publication

---

**2** [www.semanticscholar.org](http://www.semanticscholar.org) **%2**  
Internet Source

---

**3** [gis.unbc.ca](http://gis.unbc.ca) **%1**  
Internet Source

---

**4** [journals.sagepub.com](http://journals.sagepub.com) **%1**  
Internet Source

---

**5** "BLEEDING FROM THE COLON AND RECTUM", Elsevier BV, 2008 **%1**  
Publication

---

**6** [www.scribd.com](http://www.scribd.com) **%1**  
Internet Source

---

**7** [peerj.com](http://peerj.com) **%1**  
Internet Source

---

[pubmed.ncbi.nlm.nih.gov](http://pubmed.ncbi.nlm.nih.gov)

8

Internet Source

% 1

9

"Clinical Cases in Melanoma", Springer Science and Business Media LLC, 2020

Publication

% 1

10

KOSS, J. Barrie. "Absence of Chloroquine-Induced Ototoxicity in a Fetus", Archives of Dermatology, 1974.

Publication

% 1

EXCLUDE QUOTES ON

EXCLUDE BIBLIOGRAPHY ON

EXCLUDE MATCHES < 5 WORDS